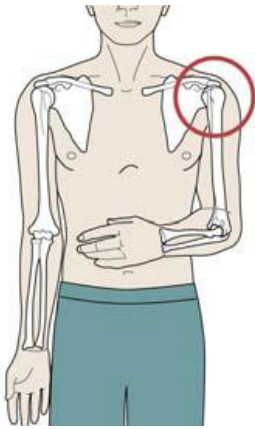
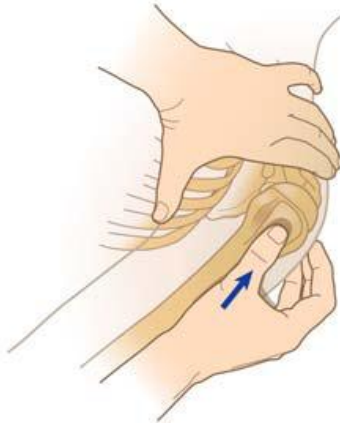

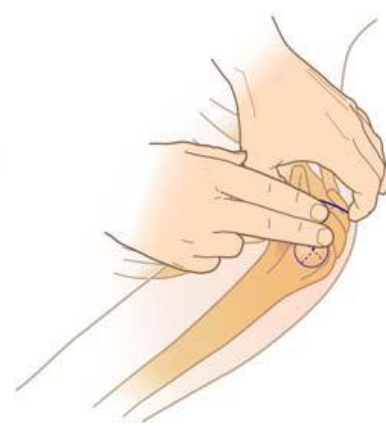Insertion site identification summary



Orient Arm



Preferred Approach



Alternate Approach

The patient should be in a supine position

1. Expose shoulder, adduct humerus (place the patient's arm against the patient's body) resting the elbow on the stretcher or ground, and have the forearm resting on the abdomen.
2. Palpate and identify the mid-shaft humerus and continue palpating toward the proximal aspect or humeral head. A small protrusion exists near the shoulder; this is the base of the greater tubercle insertion site. With the opposite hand consider "pinching" the anterior and inferior aspects of the humeral head while confirming the identification of the greater tubercle. This will ensure that the midline of the humerus itself has been identified.

Alternatively:

1. Identify two land marks on the lateral shoulder consisting of the acromion and the coracoid process. This can be accomplished by placing one hand on the lateral superior aspect of the patient's shoulder and palpating for the protrusions. Identifying the coracoid process and the acromion can also be accomplished by "walking" the index and middle fingers along the clavicle to the shoulder's lateral end.
2. Identify the greater tubercle insertion site approximately two finger widths inferior to the coracoid process and the acromion. To envision the location of this site, create a "T" - the upper portion of the letter connecting the coracoid process and the acromion while the "leg" reaches inferiorly and slightly anteriorly - approximately two finger widths along the midline between the two structures.